



Genital Piercings: What Is Known And What People with Genital Piercings Tell Us

Myrna L. Armstrong
Carol Caliendo
Alden E. Roberts

Nurses in many practice arenas are encountering clients with body piercings in visible (face and ears) and semi-visible (navel, nipple, and tongue) sites. Nurses caring for patients with urology problems are encountering more patients with body piercings in intimate sites such as the genitals. For example:

While performing a physical assessment, the professional nurse discovers that the 25-year-old female client is wearing two silver rings on her labia.

A 32-year-old male presents with a groin injury. During the examination, the urologic nurse notices several pieces of jewelry in his scrotum and penis.

As the proliferation of body piercings continues so will numbers of clients who seek care for treatment of adverse effects. These patients may present for

Nurses need information about people with genital piercings so that they may provide non-judgmental, clinically competent care. The genital piercing procedure, types of genital piercings, information found in the health care literature, and data from 37 subjects who have self-reported genital piercings are presented.

health care for a variety of physical conditions, including piercing-related infections, bleeding, nerve damage, or allergic reactions (Meyer, 2000).

For health care providers, the physical aspects of treatment and care may pose a dilemma, but so might their personal reaction to the genital piercings. The authors have overheard the following types of responses to the above sample client interactions, "Why would someone do such a thing?" and "Are these people normal?" Others have been heard to exclaim, "They must be sex fiends," or "Watch out! These people have lots of STDs and other awful diseases."

Professional nurses may not agree with or accept the practice of genital body piercing, nor make the choice to have anything but their own ears pierced. In fact, just the thought of piercing the genitals may provoke feelings of discomfort and distaste both personally and professionally.

Additionally, lack of knowledge and understanding of these client practices may challenge the nurse's ability to provide non-judgmental care. Some health professionals feel that people who choose to have body piercings deserve whatever outcome occurs (Ferguson, 1999). In contrast, this type of body art could be a meaningful part of the client's human behavior (Meyer, 2000), including a deliberate modification of one's appearance similar to what Shilling (1997) and Atkinson (2002, p. 219) call "purposive body projects."

The focus of this article is to address the (a) genital piercing procedure, (b) various types of genital piercings, (c) genital piercing information, including recent information about complications and treatment found in the health literature, and (d) data from 37 subjects who have self-reported genital piercings. These subjects were part of a larger study reported elsewhere (Caliendo,

Myrna L. Armstrong, EdD, RN, FAAN, is a Professor, Texas Tech University Health Sciences Center School of Nursing, Texas Tech University - Highland Lakes, Marble Falls, TX.

Carol Caliendo, ND, CNM, CRNP, is Dean, College of Professional Studies, and a Professor, School of Nursing, Carlow University, Pittsburgh, PA.

Alden E. Roberts, PhD, is a Professor, Department of Sociology, Anthropology, and Social Work, Texas Tech University, Lubbock, TX.

Authors' Note: Parts of this work were funded by Carlow College Office of Sponsored Programs, Iota Mu and Zeta Sigma Chapters, Sigma Theta Tau, International, and the Texas Tech University Health Sciences Center School of Nursing Research and Practice Committee.

Note: CE Objectives and Evaluation Form appear on page 180.



Armstrong, & Roberts, 2005). One aim of that research was to seek further information about individuals with genital piercings, from those who actually have genital piercings. The information contained in this article is additional anecdotal information not reported in that study.

Genital Piercing Procedure

According to Ferguson (1999), genital piercings are "largely a Western phenomenon" (p. 29). They are created similarly to general body piercings but the procedure should always be done by highly experienced piercers (Christensen, Miller, Patsdaughter, & Dowd, 2000). No state or county ordinance regarding body art in this country seems to be requiring special procedures or body piercer expertise when performing genital body procedures (Armstrong, 2005).

To perform a genital piercing, the skin is cleaned, the location marked, and a 12 to 16-gauge hollow needle (with a piece of jewelry attached to it) is threaded through the skin. As small amounts of bleeding and serosanguinous fluid usually emerge from the pierced site when the puncture track is made, hepatitis B and C will always be a potential risk (Armstrong, 2004; Tweeten & Rickman, 1998). However, the use of a new, sterile needle for each piercing and meticulous attention to universal precautions should minimize this risk. Various amounts of pain are reported at the time of piercing (Hansen, Olsen, & Langkilde, 1998).

Proper jewelry (inert nontoxic substances such as surgical stainless steel, niobium, or titanium) is important to minimize infections and allergic responses. Most quality jewelry for genital piercings is sold in the piercer's studio. Health care providers should be knowledgeable about correct removal of jewelry (a potential need with extensive

infection or trauma) as wire cutters often produce further harm to the surrounding tissue. As illustrated in Figure 1, there are two major types of jewelry: the barbell type and a captive bead. The barbell has either a curved or straight shank (or post) with balls at both ends. To remove the barbell, use a forceps to hold the shank of the jewelry, while turning the ball counter-clockwise. The captive bead type has two pieces: a bead, held in place by an incomplete metal circle. To remove this, release the tension on the bead by opening the forceps within the ring; doing this will cause the bead to "pop" out of place (Halliday, 2005). Jewelry can collect cellular debris around it so wear gloves during the removal process.

Genital sites (see Figure 1) of the foreskin, penis, scrotum, clitoris, perineum, and labia are all common areas for intimate piercings but creativity abounds in regard to genital piercing. Sometimes other pieces of "inert foreign material such as beads, or pearls, etc." (Cronin, 2001, p. 382) can also be inserted under penile tissue. These additions, called penis marbles, nodules, or bulletus, originated in Eastern cultures. Piercers will informally say that more men than women tend to obtain genital piercings but no accurate data on the actual incidence by gender is available. For men, the "Prince Albert (PA)" is a common genital piercing, which perforates the urinary meatus and corona. This frequently affects the flow and aim of the urine stream and may force men to sit during urination (Caliendo et al., 2005; Ferguson, 1999). While the PA definitely has physical disadvantages, there may be benefits as well. This type of piercing has been described as causing "an intense urethral stimulation during intercourse" (Anderson, Summerton, Sharma, & Holmes, 2003, p. 247).

Females tend to have fewer

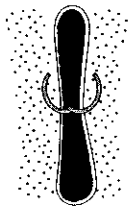
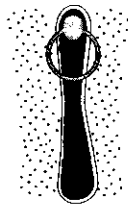
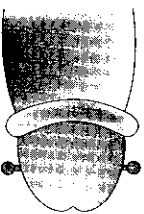


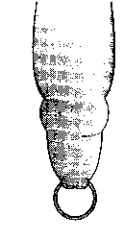
styles of genital piercings, most likely related to less tissue for any attachment of jewelry on their anatomical structures (Anderson et al., 2003). Female piercings are usually found on the hood of the clitoris and the labia (see Figure 1), although recently the "Princess Albertina," a variance on the Prince Albert, has been reported. This new piercing is done "above, or just inside the vagina orifice" (Halliday, 2005, p. 55). International medical literature frequently refers to the British law, Prohibition of Female Circumcision Act of 1985, which forbids female mutilation; Anderson et al. (2003) believe this dissuades Britain's piercers from too much creativity with female genital piercings. Stirn (2003) asserts that women with genital piercings are trying to prevent sexual contacts by guarding their body from further violation. However, a study by Millner, Eichold, Sharpe, and Lynn (2005) identified (n=33) increased frequency of sexual desire, level of desire, and level of arousal with clitoral hood piercings.

Pierced genital sites usually heal within a few weeks to months, depending on the location and amount of piercings (Anderson et al., 2003), yet infections can arise at any time, whether following the procedure, due to poor aftercare, or as a result of secondary trauma to the site. Motion in genital locations (erection of the penis) is also a factor. Any patent tract can expose a person to local infection as well as invade surrounding tissues predisposing them to systemic illness, especially if the infection is not properly treated in a timely manner. Consistent and conscientiousness daily cleansing of the site post-piercing with diluted saline solution as well as an antibacterial soap and water are important to remove most harmful organisms and accumulation of discharge.

Sexual activity should be



Figure 1.
Common Types of Genital Piercings

Figure	Description
Female Genital	
	<i>Outer or inner labia:</i> Can be placed on any location and often done as multiple piercings. The thickness of the tissue can accommodate several pieces of jewelry, sometimes may find those that wear heavier gauge. Healing time: Inner, 1-3 months; Outer: 1-2 months.
	<i>Clit/clitoris hood:</i> The clitoris (hood) is recommended rather than the clitoral body. Direct clitoral piercing is very painful and can produce nerve damage. Either horizontal or vertical piercings are placed. This is said to produce "intense clitoral sensation during intercourse" (Anderson et al., 2003, p. 249). Healing time: 4-6 weeks.
Male Genital	
	<i>Ampallang or pallang:</i> Not a common piercing. A horizontal bar is placed through the center of the head of the penis, either thru or above the urethra. An experienced piercer is important for exact location, is painful, and can produce heavy bleeding. Healing time: 6-8 months (Anderson et al., 2003; Peate, 2000; Stewart, 2001).
	<i>Apadravya:</i> Another uncommon type of piercing. Vertical piercing through the penis shaft, behind the head, mostly between the start of the frenulum to the top of the glans. Healing time: 2-5 months (Stewart, 2001).
	<i>Dydoe:</i> Piercing is done through both sides of the rim of the glans on circumcised men. Origin might be Jewish. Healing time: 2-4 months (Anderson et al., 2003; Stewart, 2001).
	<i>Foreskin:</i> Piercing is usually done on both sides of the foreskin and closed with rings, deliberately making intercourse difficult. Healing time: 1-2 months.

avoided for at least 2 weeks. When sexual activity is resumed after healing, Stork (2002) and Meltzer (2005) both recommend the use of two condoms during intercourse to accommodate the presence of jewelry in the genital site and, thus, diminish the chance of condom breakage. Other suggested genital piercing precautions include "the use of gloves for touching...and dental dams or other appropriate barriers for oral sex" to prevent contamination from body fluids [whether from the client or partner]" (Pokorney & Berg, 1999, p. 343).


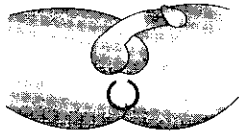

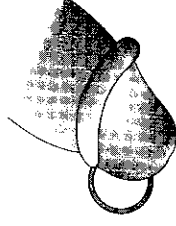

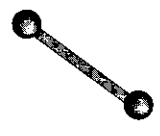

Evaluation and Treatment Of Potential Complications

Interestingly, most of the medical information regarding genital piercing complications comes from the United Kingdom, Germany, and the Scandinavian countries. It is not known if they publish more about genital piercings because they are more open about the topic, if there are more Europeans who wear genital piercings, or if more complications occur in those countries because there are less stringent piercing restrictions. Recently reported complications include a penis fistula resembling glanular hypospadiam (MacLeod & Adeniran, 2004) and a Fournier's gangrene with necrotizing fasciitis (Ekelius, Fohlman & Kalin, 2005). Paraphimosis, urethral structures, and hypertropic scarring are also frequently mentioned (Anderson et al., 2003; Jones & Flynn, 1996; Meltzer, 2005; Stewart, 2001). Placement of the correct size of jewelry must accommodate a "minimal extension of the hardware when the penis is flaccid and not impinge when the penis is in an erect state" (Halliday, 2005, p. 53). Engorgement and priapism could be present with penile rings (Meltzer, 2005).

Newly created piercings should be considered open



**Figure 1. (continued)
Common Types of Genital Piercings**

Figure	Description		
	<p><i>Frenum:</i> Easy to perform and not as painful, this is a piercing of the frenulum, or ring(s) which encircles the head of the penis which snugly fits in the groove around the glans. Not recommended for circumcised men. A variation of this is the frenum ladder, multiple barbell piercings down the midline of the penis. Healing time: 2-3 months (Anderson et al., 2003; Stewart, 2001).</p>		
	<p><i>Guiche:</i> Pronounced "geesh." Piercing done between scrotum and anus, behind the testes, usually corresponds above the inseam of pants. Healing time: 3-4 months (Meyer, 2000; Stewart, 2001).</p>		
	<p><i>Hafada:</i> Scrotal skin is pierced somewhere between the scrotum and penis with either rings or a barbell. Piercing is not considered painful, and is more decorative than sexual enhancement. Does not penetrate scrotal sac. Healing time: 2-3 months (Anderson et al., 2003).</p>		
	<p><i>Prince Albert:</i> A ring inserted through the external male urethra and out the base of the frenulum. One of the most common male genital piercings. Healing time: 1-2 months (Anderson et al., 2003, Meyer, 2000; Stewart, 2001).</p>		
Three major types of piercing jewelry worn by those with intimate piercings	 <p>Captive Bead</p>	 <p>Barbell</p>	 <p>Curved Barbell</p>

wounds and potential sites for infections. *Staphylococcus aureus* is frequently cultured from many types of infected piercing sites (Ferguson, 1999; Halliday, 2005; Meltzer, 2005). When any pierced site becomes infected,

early treatment includes leaving the jewelry in place so it can serve as a "portal for drainage and healing" (Armstrong, 2004, p. 51). When there is no resolution within a few days, further treatment is advised, usually

with a systemic antibiotic, especially if there are signs of surrounding cellulitis (Halliday, 2005).

No further information about specific treatment of genital piercings could be located. What has been documented frequently is that if treatment for infection or other complications is needed, the intimately pierced individual tends to seek consultation first from a professional body piercer rather than a health care professional (Caliendo et al., 2005). Intimately pierced individuals report strong beliefs that health care providers have limited information in regard to genital piercings (Armstrong, 2004; Caliendo, 1999; Caliendo et al., 2005).

From the Health Care Literature

Information about general body piercings has been available worldwide for many years. Yet, for genital piercings there has been limited information within the health literature (Caliendo et al., 2005). When an assumption is published, it is cited frequently without substantiated data (Armstrong, 2004; Ferguson, 1999; Stewart, 2001; Stork, 2002; Tweeten & Rickman, 1998).

From the review of literature and within the authors' own clinical practices, stereotypical assumptions about individuals who choose genital piercings are noted. These assumptions include: (a) genitally pierced persons belong to "fringe" groups and are different from people in mainstream society (Christensen et al., 2000; Falcon, 2000); (b) motives are self-harm and individuals with genital piercings are masochists (Stork, 2002; Waldron, 1998); and (c) there is a high incidence of infectious disease, such as hepatitis, HIV, and STDs (Fiumara & Eisen, 1983; Gokhale, Herson, & Ghosh, 2001; Jones & Flynn, 1996; Stork, 2002).



Figure 2.
Self-Reported Characteristics of Women and Men with Intimate Body Piercings

Aim. The purpose of this paper is to report the findings of a study exploring factors associated with female and male intimate body piercing, with particular emphasis on health issues.

Background. Nipple and genital piercings (intimate piercings) have become common types of body art. Scant medical and nursing literature is available, leading to little understanding of these body modifications by health care providers.

Method. A convenience sample of intimately pierced individuals (63 women and 83 men) from 29 states in the United States of America was surveyed via an author-developed questionnaire. Questions focused on demographic characteristics, decision factors, and health problems related to intimate piercings. Self-reported characteristics were compared between female and male participants, and participants were compared demographically to United States general population.

Results. Participants reported wearing nipple piercings (43%), genital piercings (25%), and both types (32%). Respondents were significantly younger, less ethnically diverse, better educated, less likely to be married, more often homosexual or bisexual, and they initiated sexual activity at a younger age than the U.S. population. Deliberate, individual decisions for procurement of the intimate piercings were made. Average purchase consideration was at age 25 (nipple) and 27 (genital); average age to obtain the piercing was 27 (nipple) and 27 genital. Purposes for obtaining the piercings included uniqueness, self-expression, and sexual expression. Most participants still liked their piercing (73%-90%). Health concerns related to intimate piercings were described by both those with nipple piercings (66%) and with genital piercings (52%), and included site sensitivity, skin irritation, infection, and change in urinary flow (male genital). Few STDs (3%) were reported and no HIV or hepatitis. Usually non-medical advice was sought for problems — often from the body piercer.

Conclusion. Understanding the client rationale is not a necessary prerequisite for providing quality patient care; however, awareness of purposes and decision making in intimate piercing can help nurses to be sensitive to client needs and plan appropriate health education.

Reprinted with permission from Blackwell Publishing, Ltd. Reprinted from Caliendo, C., Armstrong, M.L., & Roberts, A.E. (2005). *Journal of Advanced Nursing*, 49(5), 474-484.

Self-Reported Data from Individuals with Genital Piercings

To obtain information from those who have genital piercings, a 260-item questionnaire requesting objective and subjective data was sent to interested, intimately pierced people who answered a national or alternative newspaper advertisement. One hundred forty-six subjects participated in this study and results are reported elsewhere; a synopsis of the study appears in Figure 2

(Caliendo et al., 2005).

The current discussion concentrates on the data subset of 37 subjects who specifically self-reported only genital piercings. General demographic information includes 15 females and 22 males; age range 18 to 59 years; residence across 16 states; 84% Caucasian; and 54% single. Almost half had completed some college and a quarter had an undergraduate degree. While 63% of respondents reported church attendance when growing

up, now they rated their current religious faith in two distinct groups, either moderately strong to very strong (39%) or moderately weak to very weak (39%). Most (84%) reported good to excellent health with many (73%) having annual physical examinations.

Over half of the respondents (53%) obtained their genital piercing in their home region and paid between \$40 and \$75 for the piercing. Thirty-eight percent reported no bleeding during the actual piercing event. Pain during the procedure ranged from a small (39%) to a large amount (22%). Healing time was not asked.

Participants were asked if they considered themselves to be risk takers. One subject said "sometimes" yet another stated "I take calculated risks, not stupid ones." As to actual high-risk behavior, only 8% reported drinking or using drugs before their genital piercing procedure (routine alcohol consumption was not asked). A subject commented that it was the "policy of the artist to prohibit alcohol as it thins the blood." Almost half (49%) of the participants reported no cigarette smoking; however, 30% smoked one-half to one pack or more daily. Caliendo et al. (2005) have already reported that these respondents denied STDs, HIV, hepatitis, recurrent enlarged lymph nodes, allergies, or urinary tract infections.

While this population is unique just by having genital piercings, Caliendo et al. (2005) felt the sample did not reveal great differences from mainstream society. One subject explained:

I have three adult daughters (who are also pierced and tattooed) plus two grandchildren. We all have respectable jobs — I worked for the state for 6 years and also have my degree in British & Russian history. We



aren't deviants — we're all well-educated, family people who just live an alternative lifestyle.

Many replied, as one subject stated, "my piercing was my own desire and decision w/plenty of deliberation (over a year)"; another said "I wanted one for a long time, but it was only a few minutes when the opportunity presented itself." Another subject, a health care worker, stated:

My piercings have not affected my career. I do not discuss or bring up the topic of [genital] piercings with my patients or co-workers. My tongue piercing is far enough back that it does not inhibit my speech and is not easily seen. My tattoos are also covered and not noticeable.

The three frequently reported purposes for obtaining their piercings were sexual expression, sexual enhancement, and uniqueness (Caliendo et al., 2005). One woman said, "I'm more sexual than I use[d] to be." Another subject expressed his feelings this way:

In general, I feel good about my genital piercing. I had to enlist assistance of my partner to change out my first barbell, because the balls were screwed on too tight. Other than that, I haven't had any problems. I feel it has enhanced the degree of sexual pleasure I experience alone, or with a partner. My piercing experience was a declaration of independence, and freedom of expression, regardless of what anyone thinks of my piercing. I got it for me. It was the first decision I got to make alone. When I turned 18, my body was finally mine. I got to decorate it as I see fit. It's like moving into your own place for the first time. I can hang pictures, posters, repaint, and it's all mine. Thank you for providing me with the

opportunity to share my piercing experience.

A female stated:

My genital piercing has made me more interested in sex, and I enjoy it *a lot* more. It doesn't ever bother me, most of the time I can't even tell it's there. I also like the fact that if people know I had one they would be shocked. When you look at me, you can't see any tattoos, just my earrings and nose ring (when I wear it). A lot of people, like the people I work with, think I'm "sweet and innocent." My piercing has completely changed my sex life. I'm willing to experiment (to an extent), and I'm just more open.

Aesthetics also seemed to surface in the subjective data with both genders. The subjects spoke of "seeing it and liking it," "I liked the way it looked," "I wanted to visually enhance my vaginal labia," and "want[ing] to be unique." Another called his piercing a "new accessory for an old toy."

Almost all of the subjects reported a daily skin care routine for their genital piercings as washing with antibacterial soap and water in the shower at least once a day, then rotating the jewelry, followed by another washing and rinsing. "I wash as I always have" was a common report. Most made comments such as, "You need to keep your hands off the piercings — that's what causes problems." Emphasis also was on a thorough cleaning around the genital area following urination and bowel movements. Many of the subjects reported only removing the piercings to change the jewelry, or as one reported, for short periods of time such as for the "metal detector at the airport, surgery, and a MRI at [the] hospital."

Heavier grades of jewelry (up to 1.75 inch thick) are recommended for genital sites to sup-

port the surrounding tissue and "avoid rejection, migration, or tearing" (Armstrong, 2004 p. 50). Respondents reported wearing jewelry with gauges ranging from 2 to 14. The smaller sizes represent very heavy gauge (typically used for males), while the larger gauges tend to be used for female piercings. One subject described what could happen if a heavy enough gauge is not used:

"I got pierced by an 'apprentice' and he used the wrong gauge...18-gauge ring which turned out to be too small in diameter to pierce that kind of flesh. Thus 2 years later...the hole had stretched to about a 12 gauge or more...some piercers call that the *piano wire effect*."

Of the men (n=22) in this data subset, 17 (77%) had a Prince Albert piercing. One stated:

I personally have...a Prince Albert (PA)...It is very pleasurable for both partners during intercourse as for a male it rubs and pulls on the head of the penis and for the female adds a rigid rubbing sensation and fullness...many tell me they love their PA penis piercing except for one minor thing. During urination while standing you must hold your thumb over the point where jewelry enters the penis behind the glans, as the pressure of the urine stream will force some urine out of a small opening occasionally spraying their shoes.

Three of the males combined their Prince Albert piercing with an ampallang and apadravya (see Figure 1). Another described a frenum ladder of six barbells running horizontally toward the scrotum. No artificial penile nodules or beads were reported.

Of the 15 women with genital piercings, seven had clitoral hood piercings, while six combined clitoral hood piercings with labia piercings. One woman reported that she combined genital piercings "as a way of honor-



ing my sexuality." Another stated, "My piercings (labia and clitoris) gave me a feeling of control in my life when I needed it."

Summary

General and subjective information about those who chose to obtain genital piercings was presented. Particularly, the assumptions made from the literature are refuted by objective and subjective data collected from intimately pierced individuals themselves.

Professional nurses must not base practice decisions on assumptions but on the "best evidence with clinical experience, research, (as well as) associated patient values" (Sackett, Strauss, Richardson, Rosenberg, & Haynes, 2001, p. 10). Thus, providing clinically competent care is driven by the latest knowledge and evidence from research and patient sources. Data found here provide further empirical evidence that may help to improve client outcomes by advancing evidence-based nursing practice in relation to people with genital piercings. □

References

- Anderson, W.E., Summerton, D.J., Sharma, D.M., & Holmes, S.A. (2003). The urologist's guide to genital piercing. *BJU International*, 91(3), 245-251.
- Armstrong, M.L. (2004). Caring for the patient with piercings. *RN*, 67(6), 46-53.
- Armstrong, M.L. (2005). Tattooing, body piercing, and permanent cosmetics: A historical and current view of state regulations, with continuing concern. *Journal of Environment Health*, 67, 38-43.
- Atkinson, M. (2002). Pretty in ink: Conformity, resistance, and negotiation in women's tattooing. *Sex Roles*, 47(5/6), 219-235.
- Caliendo, C. (1999). *Female intimate body piercing: A nursing phenomenological inquiry*. Unpublished doctoral thesis. Case Western Reserve University, Cleveland.
- Caliendo, C., Armstrong, M.L., & Roberts, A.E. (2005). Self-reported characteristics of women and men with intimate body piercings. *Journal of Advanced Nursing*, 49(5), 474-484.
- Christensen, M.H., Miller, K.H., Patsdaughter, C.A., & Dowd, L.J. (2000). To the point: The contemporary body piercing and tattooing renaissance. *HT: The Magazine for Healthcare Travel Professionals*, 8(1), 38-43.
- Cronin, T.A. (2001). Tattoos, piercings, and skin adornments. *Dermatology Nursing*, 13(5), 380-383.
- Ekelius, L., Fohlman, J., & Kalin, M. (2005). The risk of several complications of body piercing should not be underestimated. *Lakartidningen*, 102(37), 2560-2562, 2564.
- Falcon, M. (2000, August 24). Genital piercing: Health-care culture shock. *USATODAY - Health*. Retrieved September 11, 2000, from www.usatoday.com/life/health/doctor
- Ferguson, H. (1999). Body piercing. *British Medical Journal*, 319, 1627-1630.
- Fiumara, N.J., & Eisen, R. (1983). The titivating penile ring. *Sexually Transmitted Diseases*, 10, 43-44.
- Gokhale, R., Heron, M., & Ghosh, A. (2001). Genital piercing and sexually transmitted infections. *Sexually Transmitted Infections: The Journal of Sexual Health & HIV*, 77(5), 393-394.
- Halliday, K.A. (2005). Body piercing: Issues and challenges for nurses. *Journal of Forensic Nursing*, 1, 47-56.
- Hansen, R.B., Olsen, L.H., & Langkilde, N.C. (1998). Piercing of the glans penis. *Scandinavian Journal of Urology and Nephrology*, 32, 219-220.
- Jones, S.A., & Flynn, R.J. (1996). An unusual (and what piercing) cause of paraphimosis. *British Journal of Urology*, 78, 803.
- MacLeod, T.M., & Adeniran, S. (2004). An unusual complication of penile piercing: A report and literature review. *British Journal of Plastic Surgery*, 57(5), 462-464.
- Meyer, D. (2000). Body piercing: Old traditions creating new challenges. *Journal of Emergency Nursing*, 26(6), 612-614.
- Meltzer, D.J. (2005). Complications of body piercing. *American Family Physician*, 72(10), 2029-2036.
- Millner, W.S., Eichold, B.H., Sharpe, T.H., & Lynn, S.C. (2005). First glimpse of the functional benefits of clitoral hood piercings. *American Journal of Obstetrics and Gynecology*, 193(3), 675-676.
- Peate, I. (2000). Body piercing: Could you answer your patient's questions? *British Journal of Nursing*, 9(20), 28-36.
- Pokorney, C., & Berg, R. (Eds.). (1999). *Body art: A comprehensive guidebook and model code*. Denver, CO: National Environmental Health Association.
- Sackett, D.L., Strauss, S.E., Richardson W.S., Rosenberg, W., & Haynes (2001). *Evidence-based medicine: How to practice and teach EBM*. London: Churchill Livingstone.
- Shilling, C. (1997). The body and difference. In K. Woodward (Ed.), *Identity and difference* (pp. 63-121). London: Sage.
- Stewart, C. (2001). Body piercing: Seductions and medical complications of a risky practice. *Medical Aspects of Human Sexuality*, 1(5), 45-50.
- Stirn, A. (2003). Medical consequences and psychological motivations. *The Lancet*, 361(9364), 1205-1215.
- Stork, B. (2002). Medical complications of modern art: What you need to know about body piercing. *Advance for Nurse Practitioner*, 10(1), 59-64.
- Tweeten, S.S.M., & Rickman, L.S. (1998). Infectious complications of body piercing. *Clinical Infectious Diseases*, 26(3), 735-740.
- Waldron, T. (1998). Tattoos, body piercing are linked to psychiatric disorders in youth. *The Brown University Child and Adolescent Behavior Letter*, 14(7), 1-4.

CE test located on page 180.

Need CE Credit?
Visit the "Education"
section at
www.sun.org



UNJ J608

Answer/Evaluation Form: Genital Piercings: What Is Known and What People With Genital Piercings Tell Us

This test may be copied for use by others.

COMPLETE THE FOLLOWING:

Name: _____

Address: _____

City: _____ State: _____ Zip: _____

Preferred telephone: (Home) _____ (Work) _____

SUNA Member Expiration Date: _____

Registration fee: SUNA Member: \$12.00
Nonmember: \$20.00

Answer Form:

1. If you applied what you have learned from this activity into your practice, what would be different?

Evaluation

- | | Strongly
disagree | | | | Strongly
agree |
|-----------------------------------------------------------------------------------------------------|----------------------|---|---|---|-------------------|
| 2. By completing this activity, I was able to meet the following objectives: | | | | | |
| a. Describe the genital piercing procedure. | 1 | 2 | 3 | 4 | 5 |
| b. Discuss the evaluation and treatment of potential complications resulting from genital piercing. | 1 | 2 | 3 | 4 | 5 |
| c. Discuss self-reported data from individuals with genital piercings. | 1 | 2 | 3 | 4 | 5 |
| 3. The content was current and relevant. | 1 | 2 | 3 | 4 | 5 |
| 4. The objectives could be achieved using the content provided. | 1 | 2 | 3 | 4 | 5 |
| 5. This was an effective method to learn this content. | 1 | 2 | 3 | 4 | 5 |
| 6. I am more confident in my abilities since completing this material. | 1 | 2 | 3 | 4 | 5 |
| 7. The material was (check one) ___new ___review for me | | | | | |
| 8. Time required to complete the reading assignment: _____minutes | | | | | |

I verify that I have completed this activity: _____ Signature

Comments

Objectives

This educational activity is designed for nurses and other health care professionals who care for and educate patients and their families about genital piercings. For those wishing to obtain CE credit, an evaluation follows. After studying the information presented in this offering, you will be able to:

1. Describe the genital piercing procedure.
2. Discuss the evaluation and treatment of potential complications resulting from genital piercing.
3. Discuss self-reported data from individuals with genital piercings.

Posttest Instructions

1. To receive continuing education credit for individual study after reading the article, complete the answer/evaluation form to the left.
2. Photocopy and send the answer/evaluation form along with a check or money order payable to **SUNA** to *Urologic Nursing*, CE Series, East Holly Avenue Box 56, Pitman, NJ 08071-0056.
3. Test returns must be postmarked by June 30, 2008. Upon completion of the answer/evaluation form, a certificate for **1.5** contact hour(s) will be awarded and sent to you.

This activity has been provided by the Society of Urologic Nurses and Associates (SUNA). SUNA is accredited as a provider of continuing nursing education by the American Nurses' Credentialing Center's Commission on Accreditation (ANCC-COA). SUNA is a provider approved by the California Board of Registered Nurses, provider number CEP 05556. Licenses in the state of CA must retain this certificate for four years after the CE activity is completed.

This article was reviewed and formatted for contact hour credit by Sally S. Russell, MN, CMSRN, SUNA Education Director; and Jane Hokanson Hawks, DNSc, RN, BC, Editor.

I am an (check one)

RN APN LPN/LVN AP

Other _____